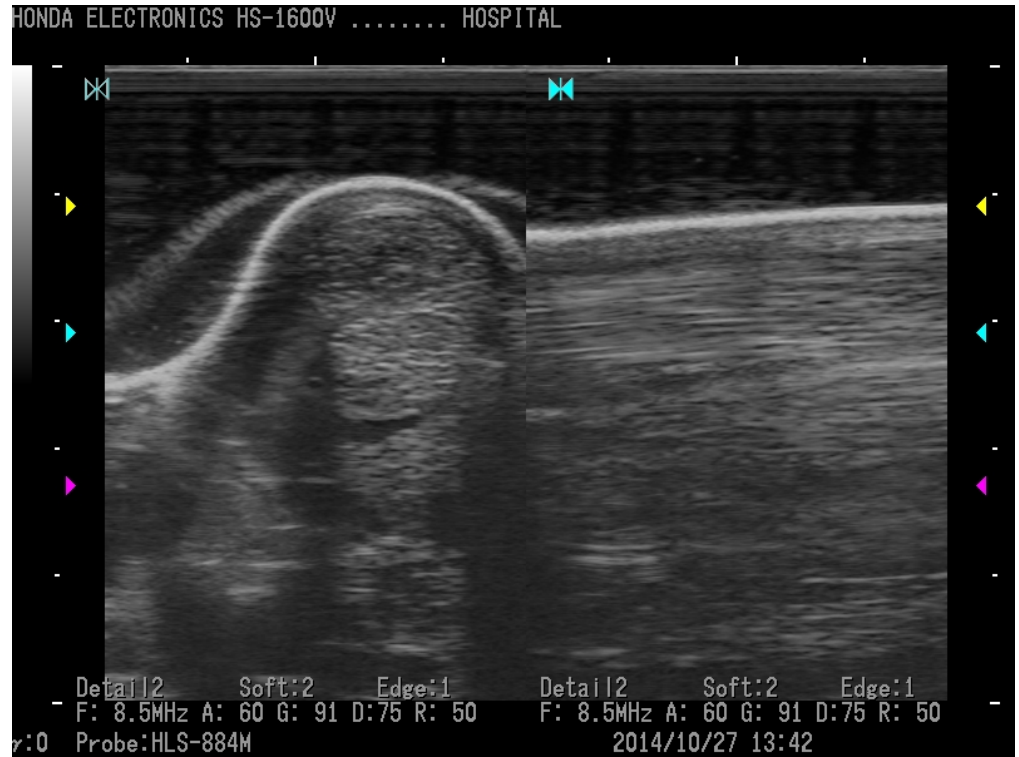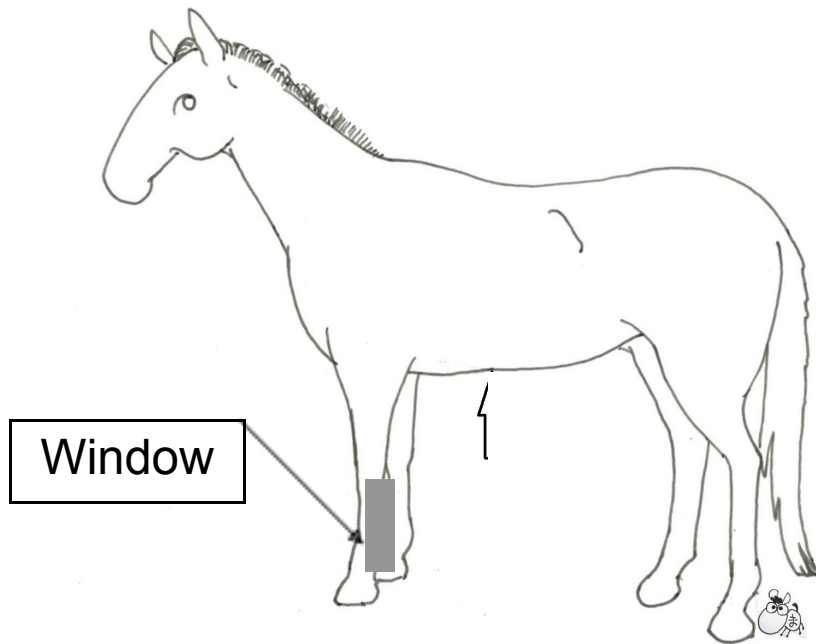

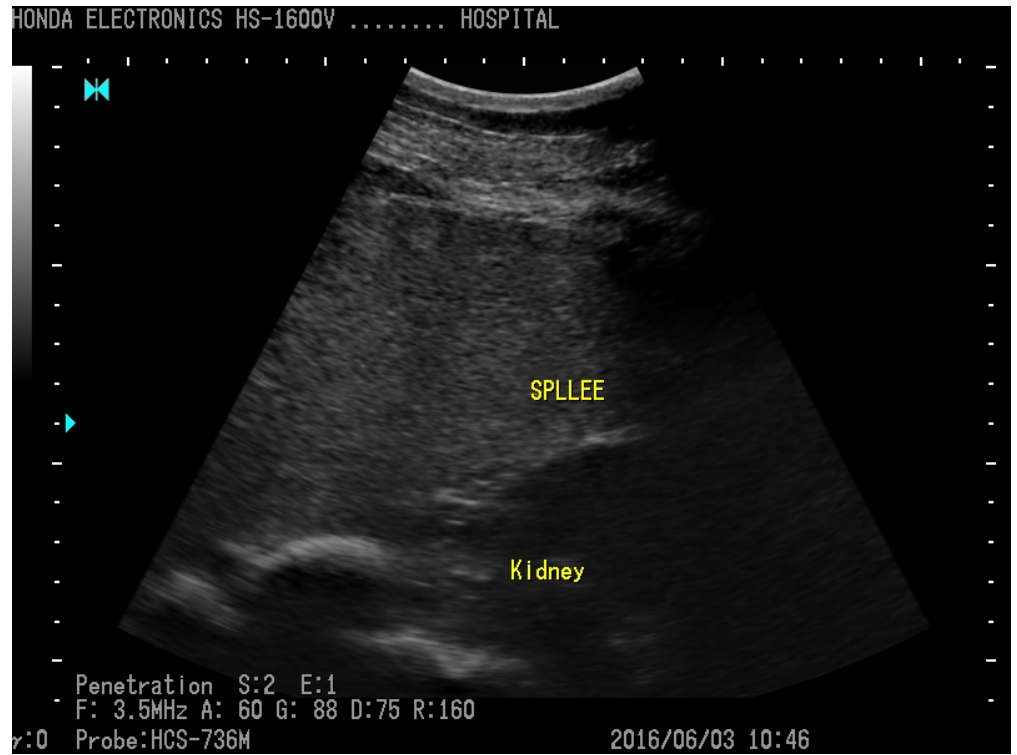


Tendon



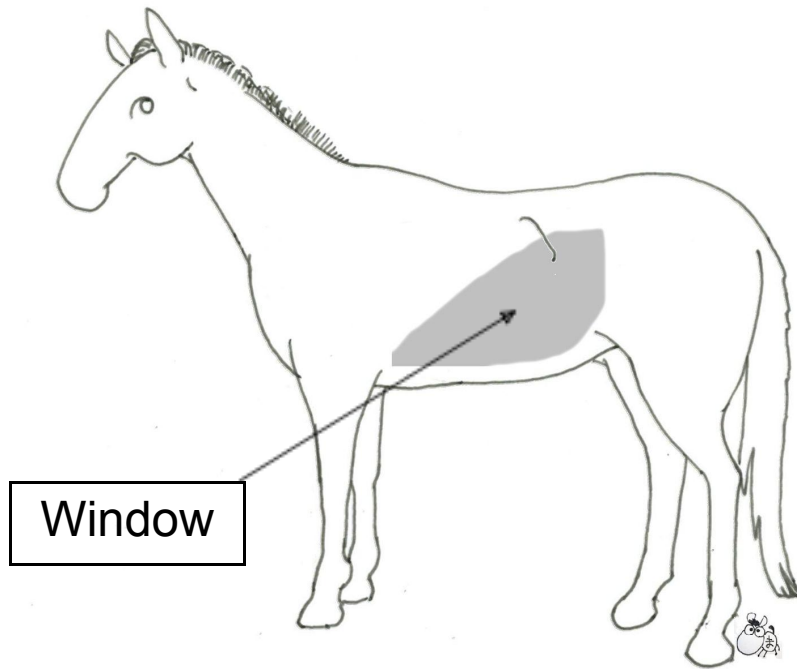
Linear (HLS-884M)

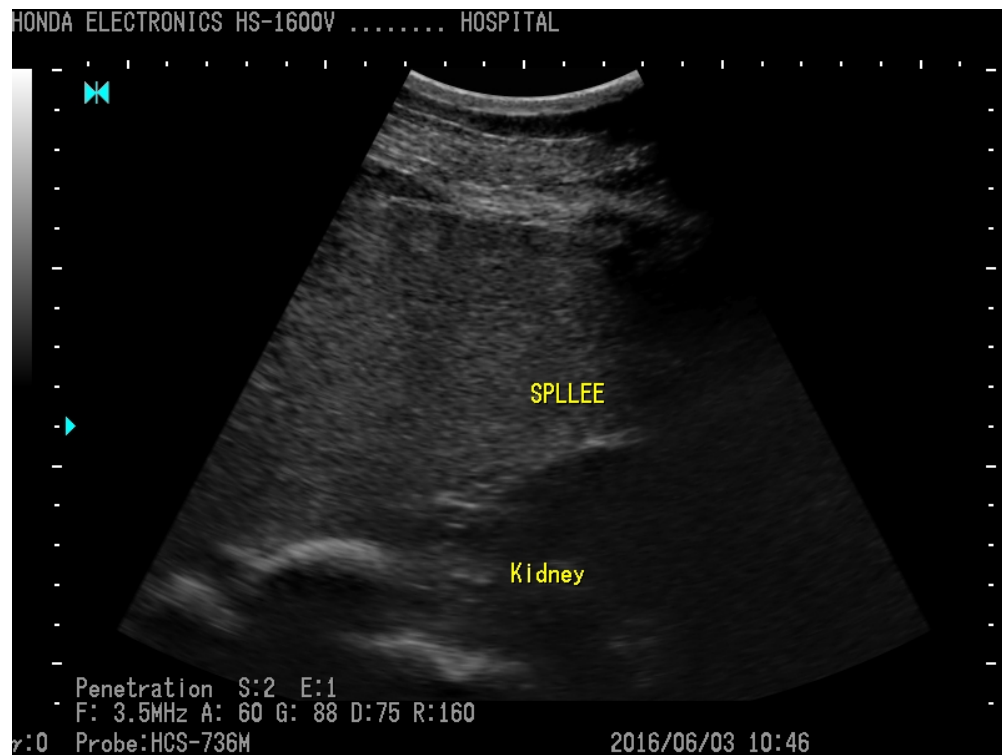

Spleen



Convex (HCS-736M)

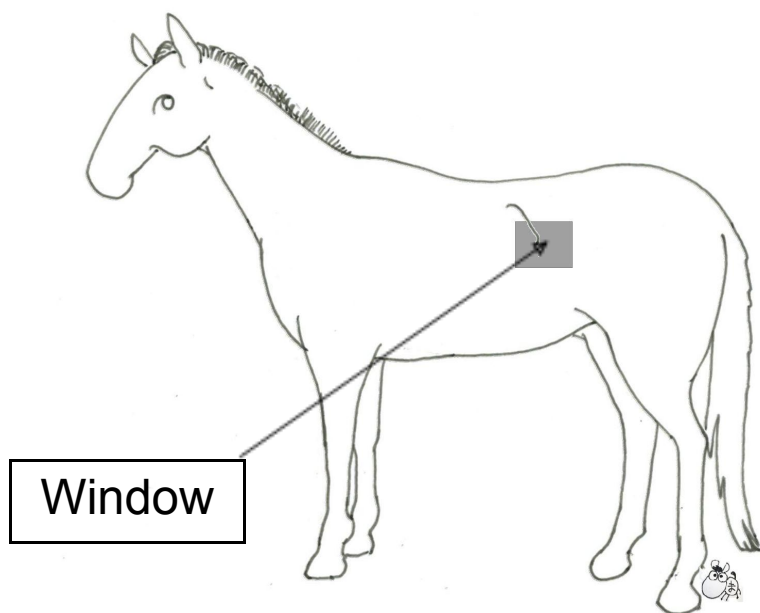


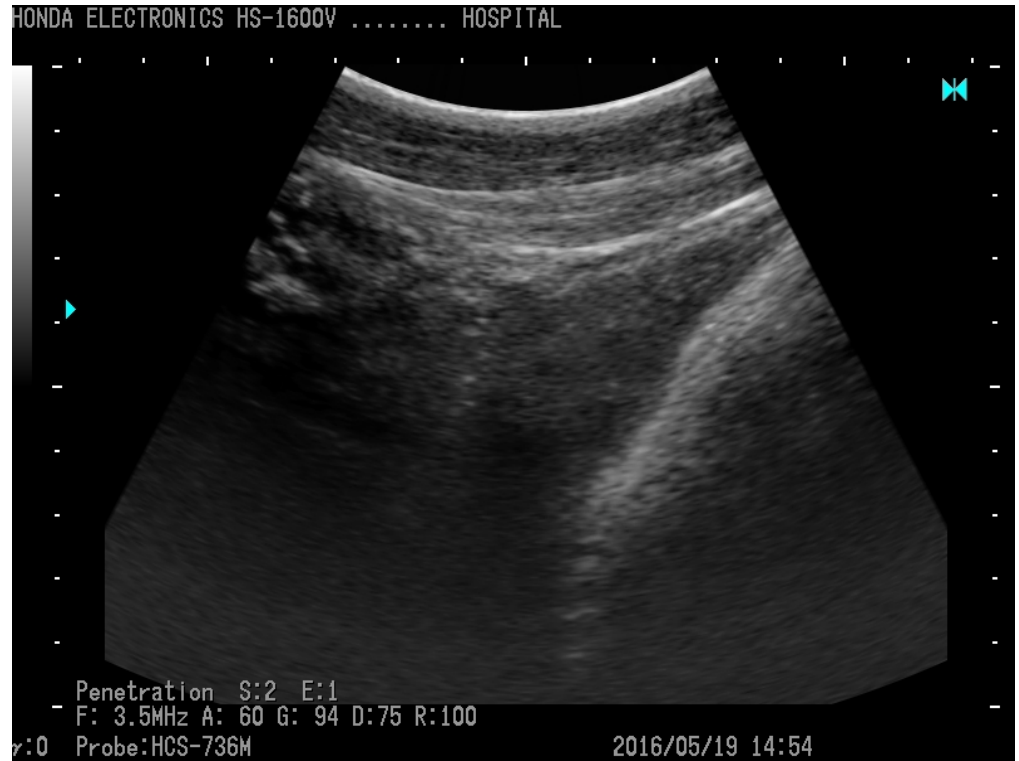

Left Kidney

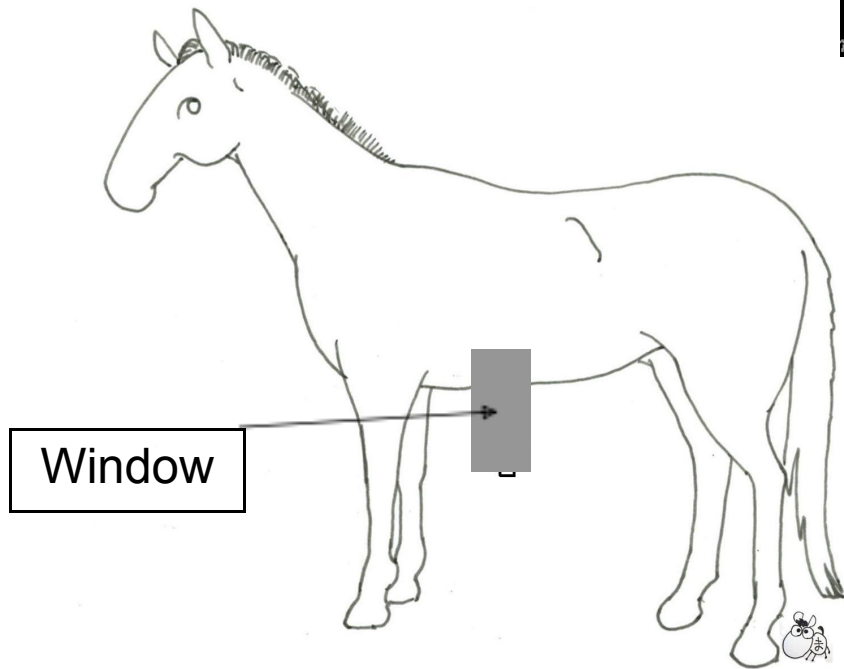


Convex (HCS-736M)

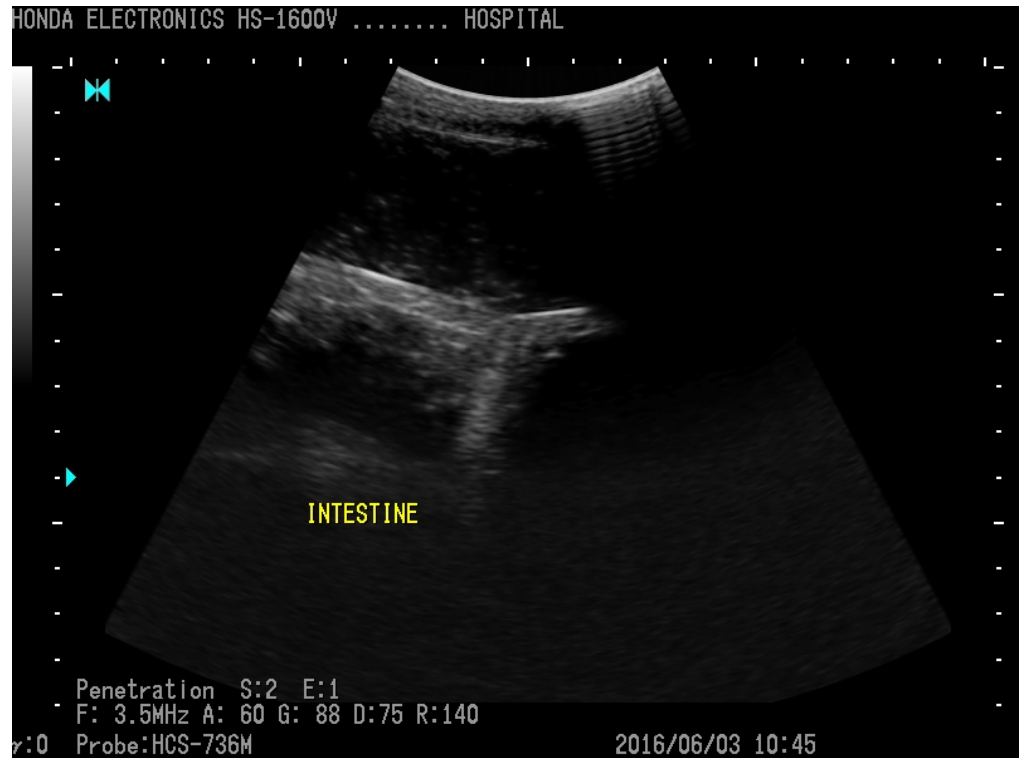



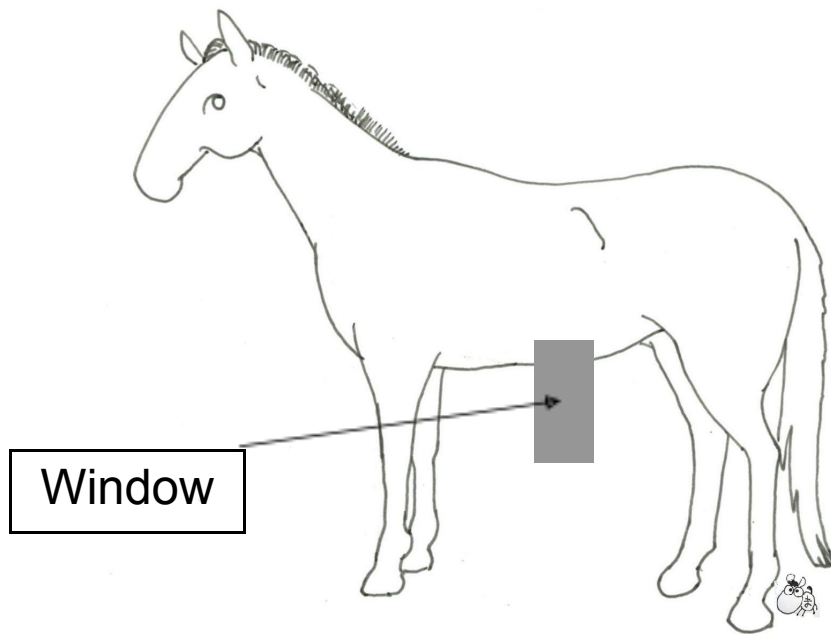
Gastric fundus



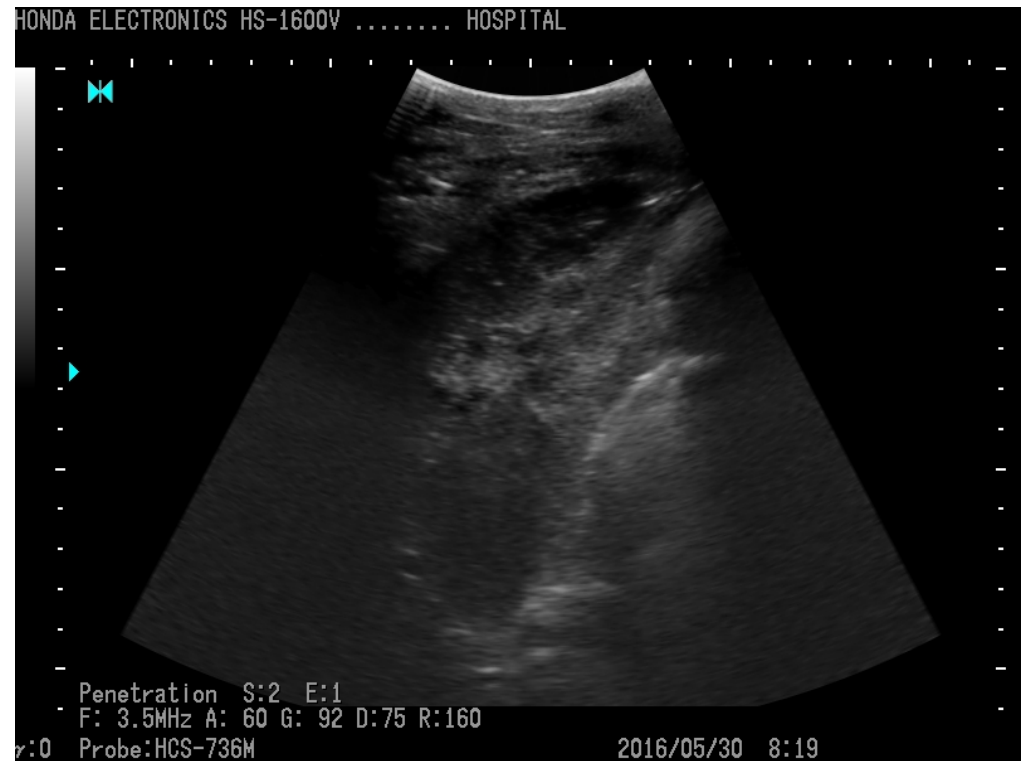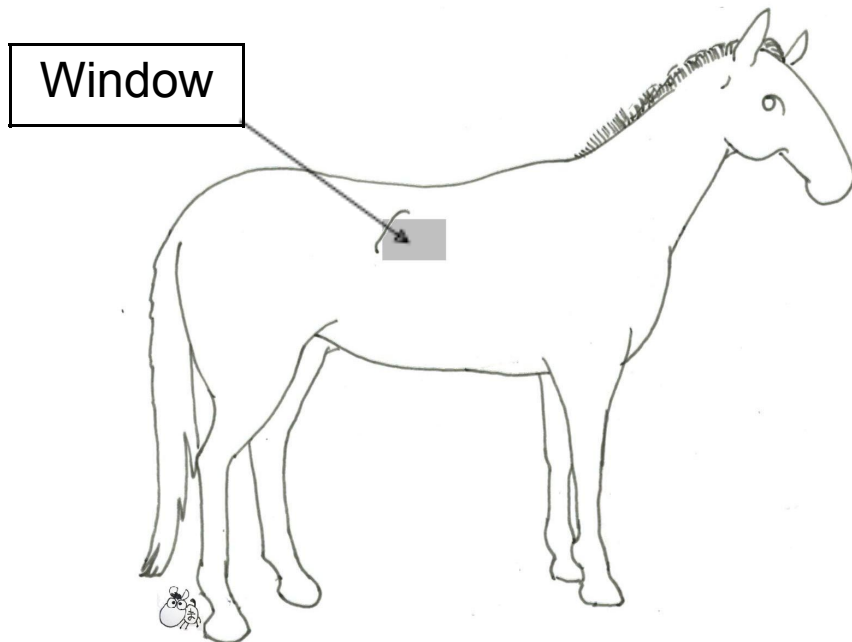
Convex (HCS-736M)



Intestine



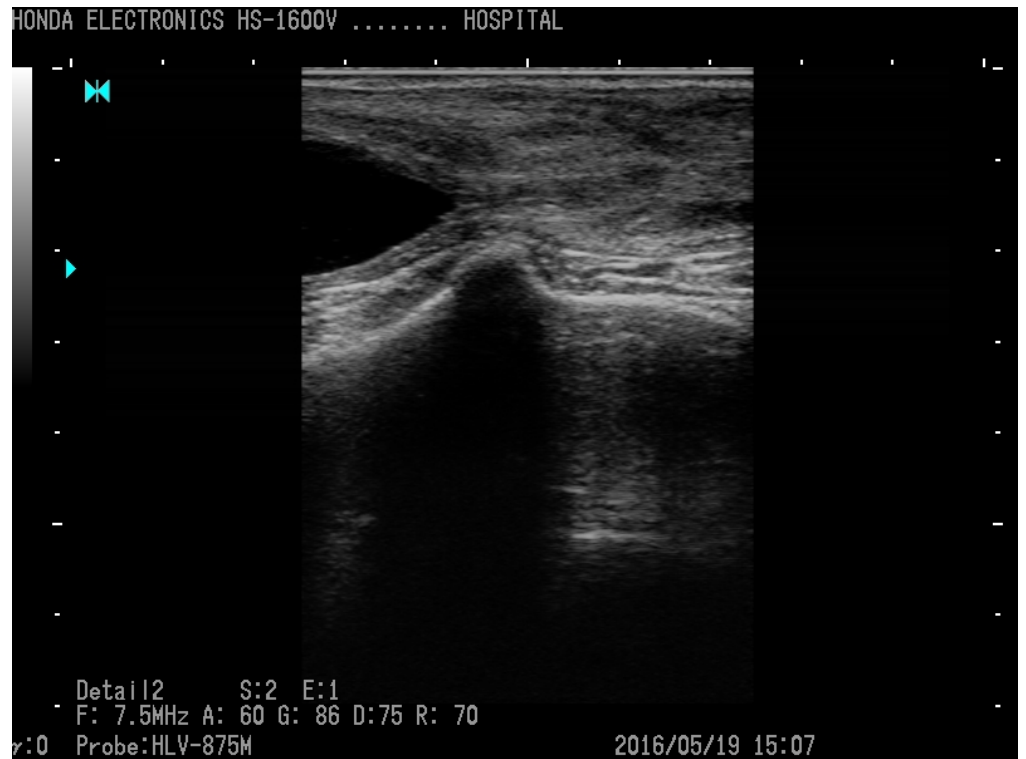Observation of right kidney  
between 14th and 16th rib.  
Intestine duodenum is observed  
from the abdominal side of right  
kidney



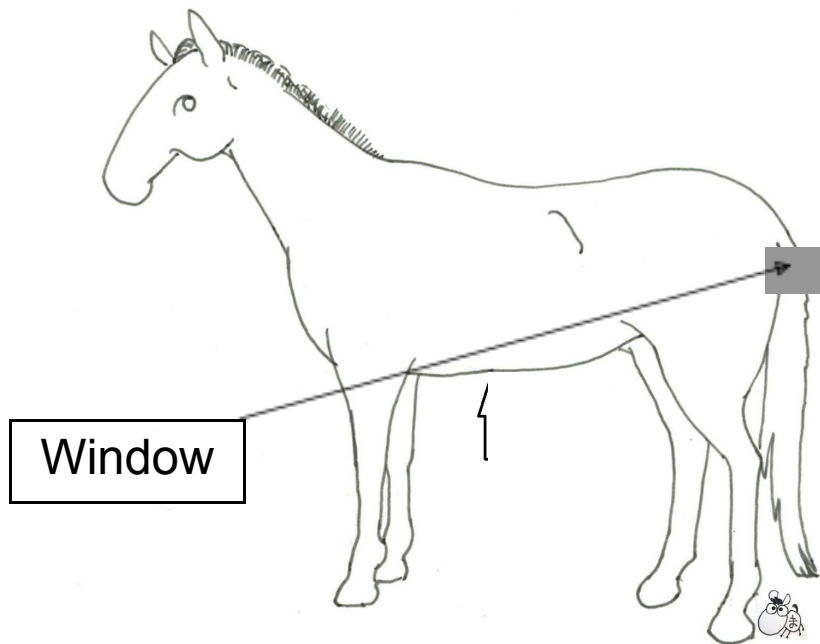
Right Kidney



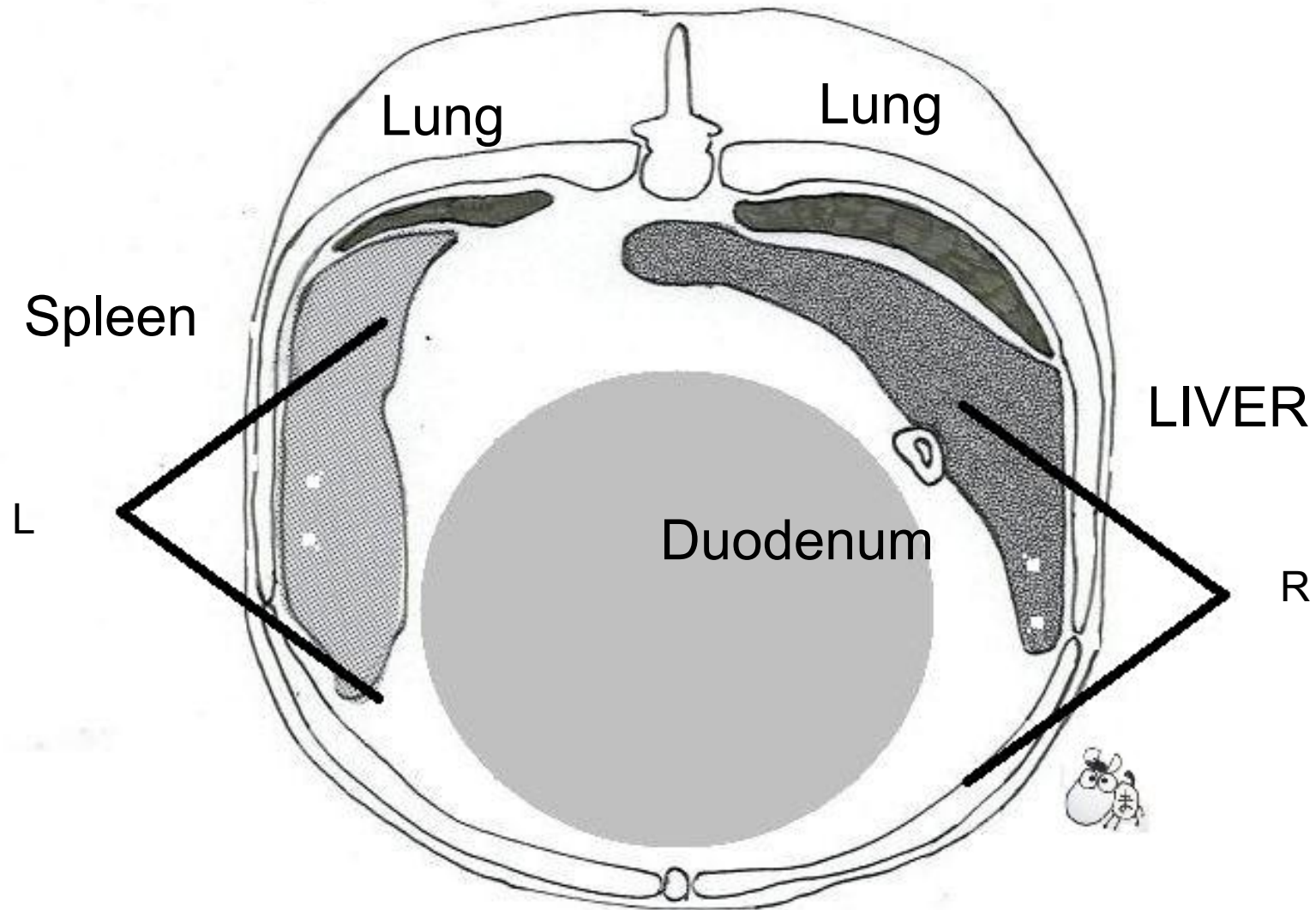
Convex (HCS-736M)



Bladder and Prostate

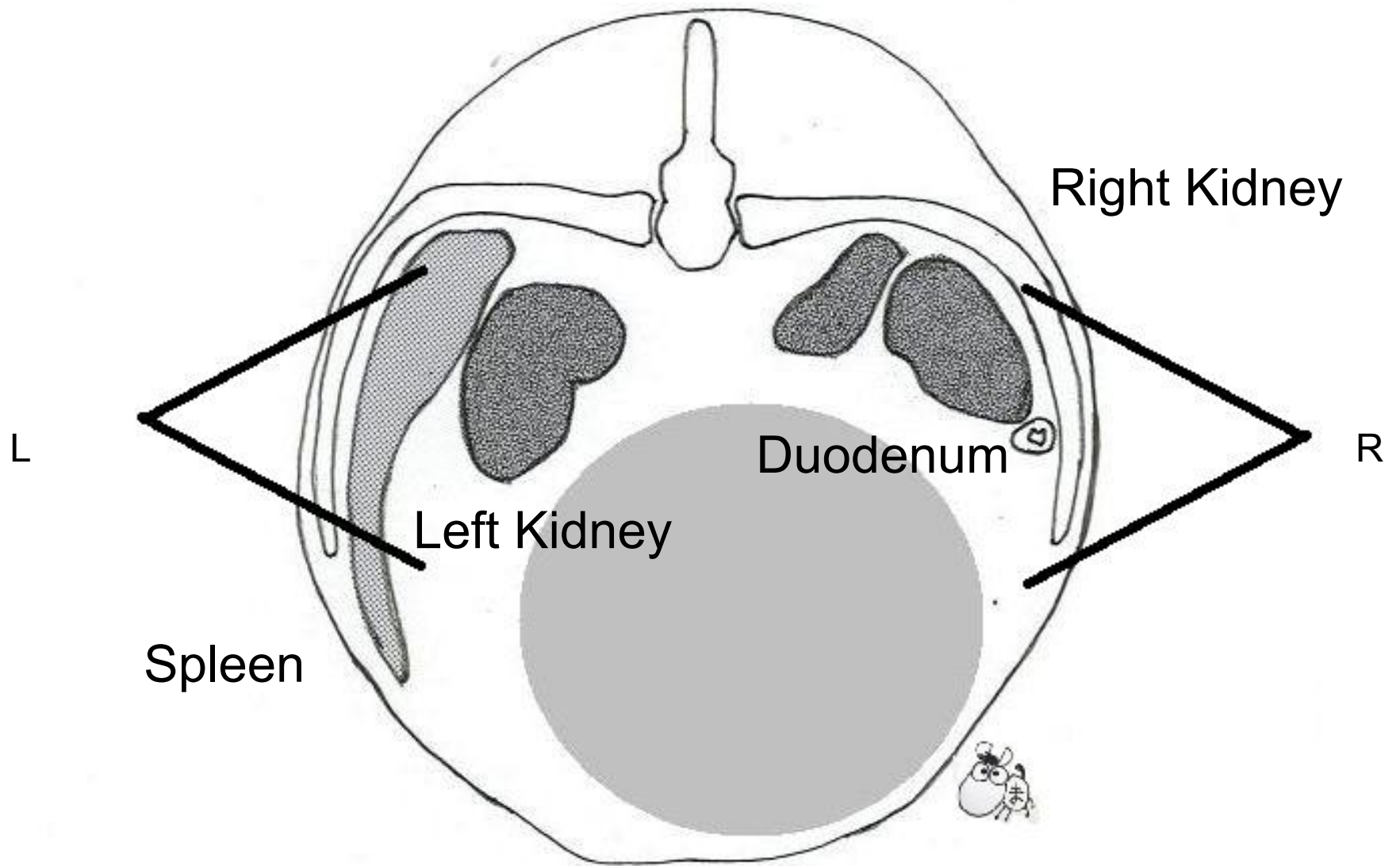


Rectal Probe (HLV-875M)

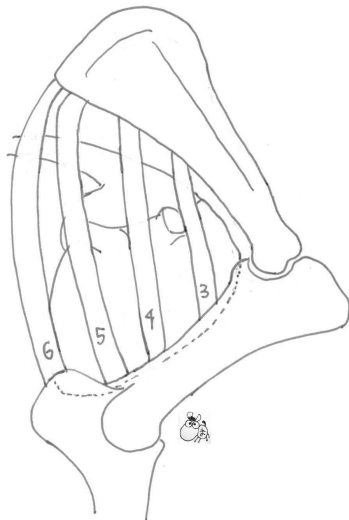
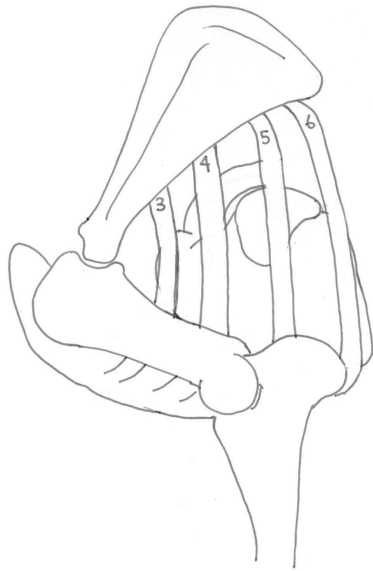


X-section pictures between the 13th rib.  
Center gray circle is the area of alimentary canal.

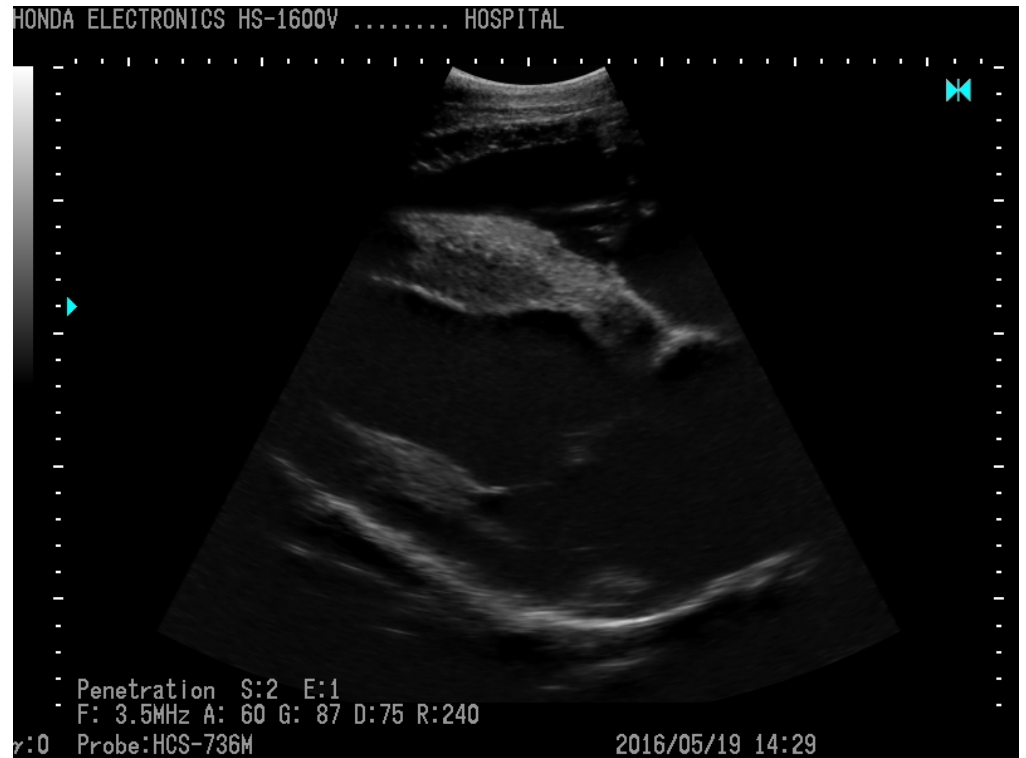



X-section pictures between the final ribs.  
Center gray circle is the area of alimentary canal.



Scan the position between the 4th ribs correctly by convex probe



Heart (4 chamber)



Convex (HCS-736M)